

## An Active Dynamic Thermography (ADT) method for TRAM flap blood perfusion mapping in breast reconstruction

By M. Moderhak\*, Sz. Kołacz\*\*, J. Jankau and T. Juchniewicz

\* Gdansk Univ. of Technology, 80-233, Narutowicza Str., Gdansk, Poland, matmod@biomed.eti.pg.gda.pl

\*\* Gdansk University of Medicine, ul. Debinki 7, 80-211, Gdansk, Poland, skolacz@gmail.com

### Abstract

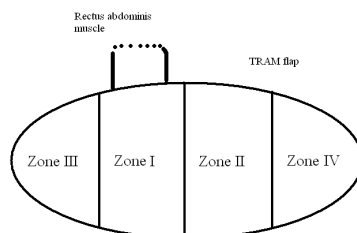
This paper presents a new method of TRAM flap blood perfusion mapping based on the Active Dynamic Thermography (ADT). This method is aimed at aiding the surgeon during breast reconstruction procedure. A pair of dTnorm and t90\_10 parameters were used as parametric image descriptors. Their properties were examined by means of computer simulation and modelling. The method was tested on 38 patients that were subjected to breast reconstruction procedure. This showed this is potentially an objective and effective method of skin flap perfusion assessment that can be performed in the operating room.

### 1. Introduction

One of the problems in plastic surgery is tissue reconstruction in patients that underwent cancerous breast resection. The most popular method of such reconstruction is based on unipedicled skin flap transplant to the target area. Among different reconstructions the unipedicled transverse rectus abdominis musculocutaneous (TRAM) flap breast reconstruction is one of the most important ones. The flap utilizes blood flow through the deep superior epigastric pedicle within the rectus abdominis muscle [1]. Three different techniques of unipedicled flap method are used in this type of reconstruction: IPSI where skin flap is taken with the rectus abdominis muscle that is located at the same side as the reconstructed breast, CONTRA where the flap is extracted within the muscle diagonally and TRAM supercharged where the deep superior epigastric pedicle is microsurgically connected with internal thoracic artery [1] - such coupling provides better blood perfusion in the reconstructed area and reduces the risk of flap necrosis.

### 2. Problems

In the discussed breast reconstruction technique proper flap blood perfusion evaluation is essential for avoiding flap necrosis. Currently the most popular methods of skin flap evaluation are based on subjective evaluation such as: tissue color, respecting flap perfusion zones guidelines shown in figure 1. In the abdominal skin flap 4 zones of different perfusion can distinguished: zone IV has poor blood perfusion and it is usually not considered for reconstruction. Blood perfusion in zones II and III strongly depends on each patient's anatomy. Zone I is considered to be the most reliable for reconstruction [2].




**Fig. 1.** Perfusion zones of the TRAM skin flap; Zone I is the most reliable and zone IV is least suited for reconstruction

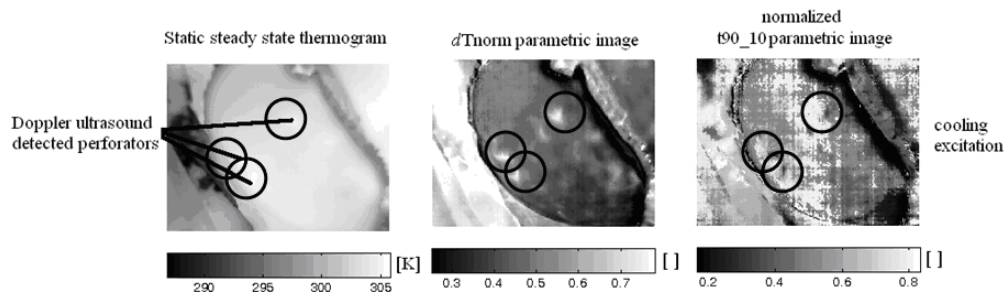
The ideal method for flap imaging should be: patient and flap safe, non-invasive, repeatable, fast as well as yielding low purchase and exploitation costs [3]. Among available methods such as: angiography, angio-CT, on indocyanine green dye [4], [5] and MRI, Laser Doppler Imaging (LDI) and thermography [6], which is the closest to fulfilling these requirements. Its functional imaging possibilities it enables flap thermal activity monitoring which is directly connected to body blood perfusion and metabolism [7], [8], [9]. Thermography is also relatively cheap compared to other techniques like LDI.

## 2. Methodology, results

A parametric imaging method based on simplified parameterization of thermal transient processes [10], [11], [12] was proposed to qualify blood perfusion in elevated, unipedicted TRAM flap. Its properties were examined by simulating an ADT exam on a skin flap computer model (example results are shown in figure 2). This approach was then tested in the operating room, during breast reconstruction procedure of 38 patients. The thermal sequences containing both the excitation and natural temperature return phase was recorded and transformed into a pair of parametric images  $dT_{norm}$  and  $t90_{10}$ . The images were referenced with Ultrasound Doppler exam of real skin flaps results as shown in figure 3. It proved it to be an effective and reliable tool for skin flap perfusion imaging.



**Fig. 2.** Example results of TRAM flap parametric imaging performed on the data obtained via computer simulations



**Fig. 3.** Static thermography imaging versus ADT parametric  $dT_{norm}$  and  $t90_{10}$  images confronted with USG Doppler; Ultrasound detected perforators are encircled black in each picture; ADT results match with Doppler results and reveal more potential perforators

## REFERENCES

- [1] Grabb and Smith, Plastic Surgery, 7th edition, Chapter 61, page 643
- [2] Hartrampf CR Jr, Schefflan M, Black PW. Breast reconstruction with a transverse abdominal island flap. *Plast Reconstr Surg*. 1982;69:216-225
- [3] Creech, B., and Miller, S. Evaluation of Circulation in Skin Flaps. In W. C. Grabb and M. B. Myers (Eds.), *Skin Flaps*. Boston: Little, Brown, 1975
- [4] S. Yamaguchi, F. De Lorenzi, J. Y. Petit, M. Rietjens, C. Garusi, A. Giraldo, P. C. Rey, C. Urban, S. Martella, R. Bosco, The "Perfusion Map" of the unipedicted TRAM Flap to Reduce Postoperative Partial Necrosis, *Annals of Plastic Surgery*, vol. 53, 2004, (205–209)
- [5] Miland A, Weerd L, Weum S, Mercer J. Visualising skin perfusion in isolated human abdominal skin flaps using dynamic infrared thermography and indocyanine green fluorescence video angiography. *E J of Plastic Surgery* Oct 2008, Vol 31, Issue 5, pp 235-242
- [6] A. Nowakowski, Quantitative Active Dynamic Thermal IR-Imaging and Thermal Tomography in Medical Diagnostics. *The Biomedical Engineering Handbook*. Third Edition. Medical Devices and Systems. ed. J. B. Bronzino, 22–1, CRC, 2006.
- [7] H. H. Pennes, Analysis of tissue and arterial blood temperature in the resting forearm. *Journal of Applied Physiology*. vol. 1 1948, (93–122)
- [8] Khouri RK, Shaw WW. Monitoring of free flaps with surface-temperature recordings: Is it reliable? *Plast Reconstr Surg* 1992; 89:495
- [9] Jones BM. Monitors for the Cutaneous Microcirculation. *Plast Reconstr Surg* 1984;73:843
- [10] M. Moderhak, Analiza algorytmów diagnostyki termicznej w mammografii, PhD, Gdansk University of Technology 2013
- [11] M. Moderhak, A. Nowakowski, P. Siondalski, M. Kaczmarek, Ł. Jaworski, Active Dynamic Thermography imaging of wound healing processes in cardio surgery, *Advances in Intelligent Systems and Computing*, vol.284
- [12] A. Nowakowski, P. Siondalski, M. Moderhak, M. Kaczmarek, A new diagnostic method for evaluation of cardiosurgery wound healing, *Quantitative InfraRed Thermography Journal* 09/2015;